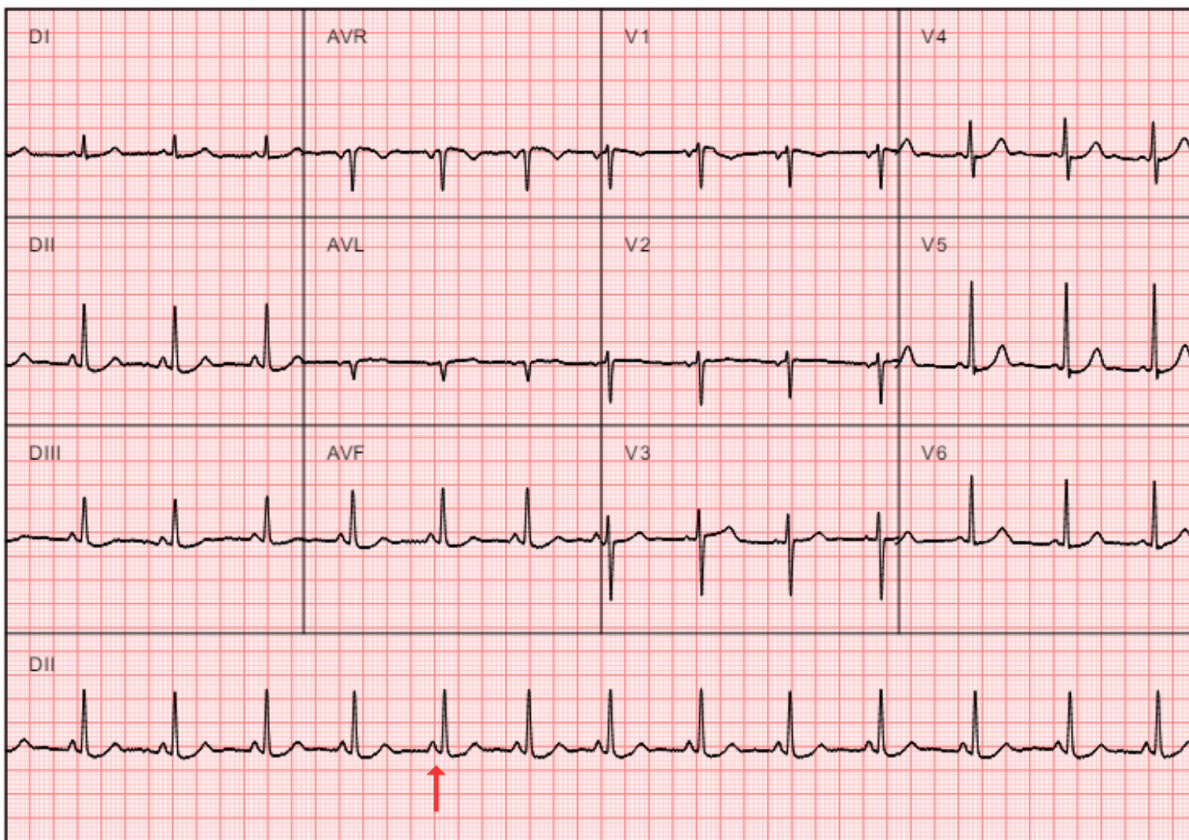


# Exemplos | Examples 1

## Exemplo 1 | Exemplo #1

Paciente feminina, 43 anos, com queixa de palpitações. Ao ECG, apresenta ritmo sinusal regular, com **intervalo PR curto**, menor que 200 ms.

*Female patient, 43 years old, presents with palpitations. The ECG shows a regular sinus rhythm with a short PR interval (<200 ms).*



Revision #6

Created 22 May 2025 17:36:04 by Gabriela Miana

Updated 13 October 2025 17:49:08 by Gabriela Miana